

Joanna Jakubaszko-Jabłońska

ENVIRONMENTAL EMERGENCIES

Chair of Emergency Medicine
Wroclaw Medical University



Polskie Towarzystwo
Medycyny Ratunkowej

Polish Society for
Emergency Medicine

Emergency treatment of near-drowning victims

Clinical findings:

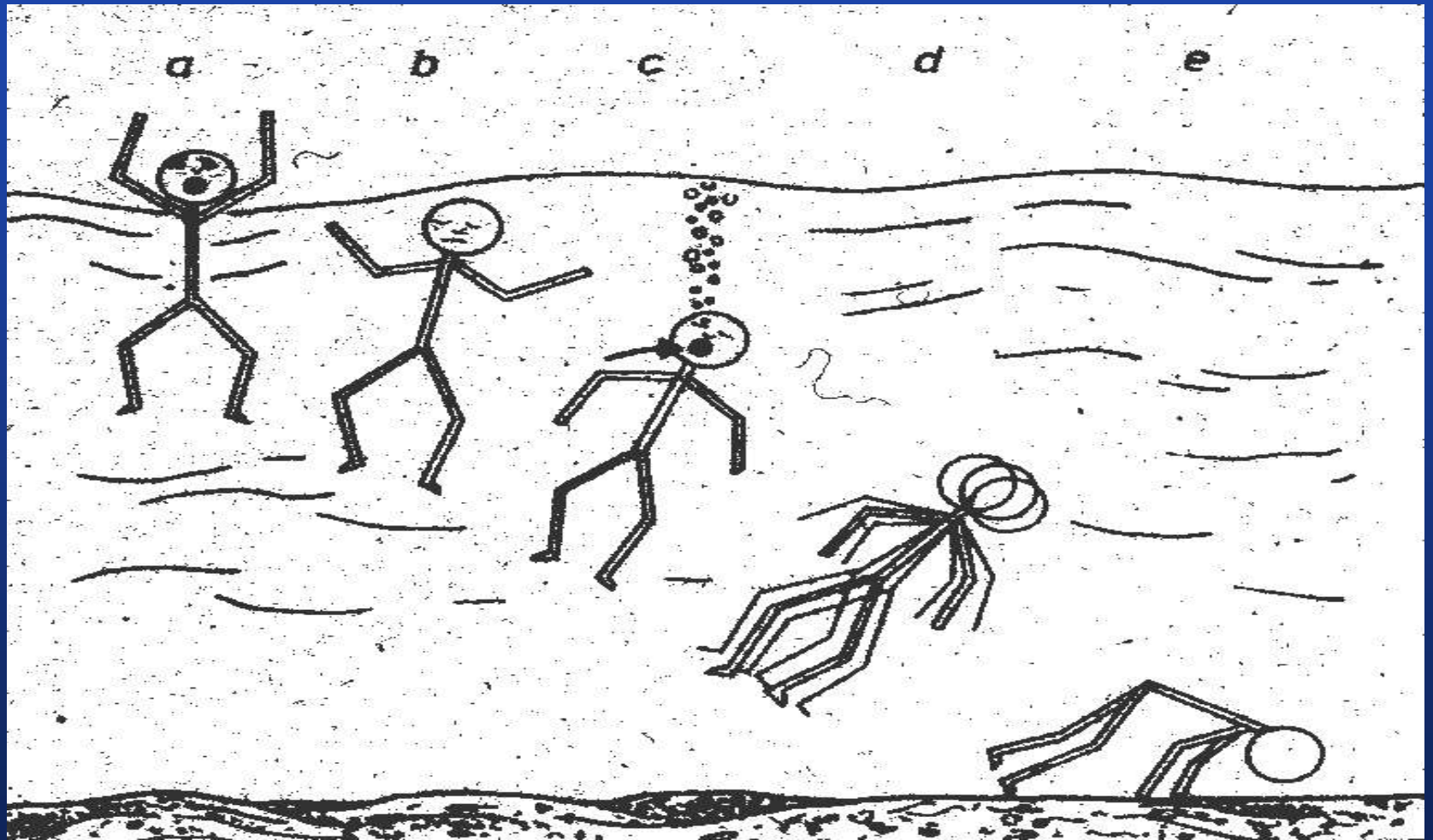
The victim may present with a wide range of clinical manifestations.

Vomiting, loss of consciousness;

more severe patients may develop ARDS, hypoxic encephalopathy or cardiac arrest.

Emergency treatment of near-drowning victims

Some patients may be asymptomatic and deteriorate as a result of acute respiratory failure in the 6-24 h.



Near-drowning victims

Symptoms and signs:

cyanosis, apnea, tachypnea may be present.

A pink froth from the mouth and nose indicate pulmonary oedema.

Cardiovascular manifestations may include tachycardia, arrhythmias, hypotension, shock and cardiac arrest.

Electrolyte disturbances are found.

Near-drowning victims

Initial chest X-rays may show aspiration of fluid.

Late findings may betray pulmonary oedema or ARDS.

Renal failure and rhabdomyolysis may also evolve.

Treatment of near-drowning victim

- Extract the victim from water in prone position. Potential circulatory collapse exist with sudden removal of surrounding water pressure in the upright position.
- Cervical spine immobilization should be maintained in shallow water, surfing or trauma victims.
- Open the airway and maintain ventilation. Give oxygen.
- Establish circulation
- Treat hypothermia

Near-drowning victims

who are initially asymptomatic must be monitored for respiratory distress that develops typically within 6h.

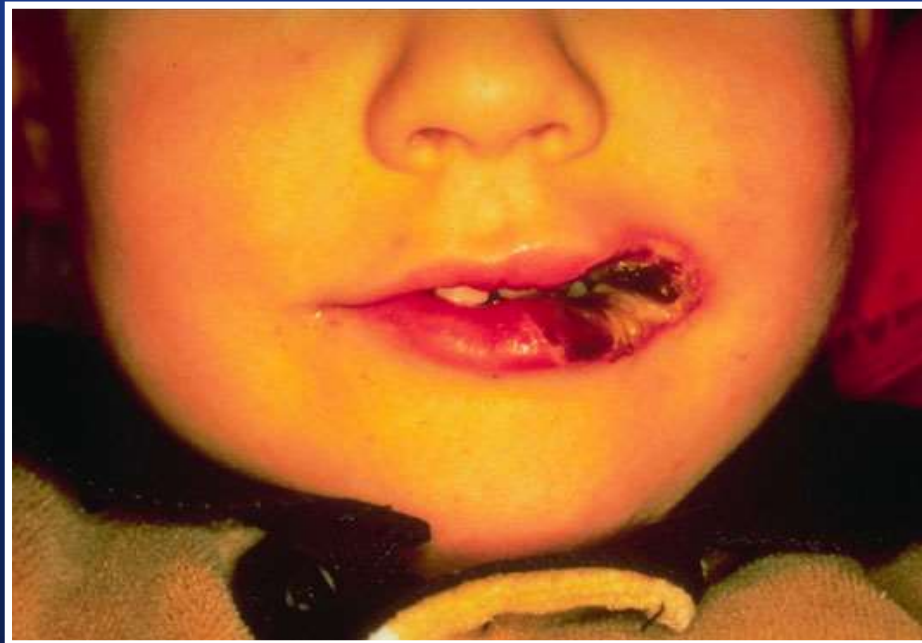Electric shock and burns

- essentials of diagnosis:

- direct current is less dangerous than alternating current (AC, most house current)
- AC can cause ventricular fibrillation and respiratory arrest
- burns can result from electrical current and, although they may look mild, can indicate significant internal damage
- treatment includes CPR, wound care

Electric shock injuries include:

- workplace injuries
- children handling or mouthing electric cords and outlets



Electric shock injuries

AC causes tetanic muscle contractions that may prolong contact with the source and travel from the victim to a rescuer.

Electric shock injuries

Clinical findings:

- electric shock- leads to cardiac arrhythmias, deafness, blindness, aphasia, neuropathy, multiple ortopedic injuries
- electrical burns – small direct electrical burn may hide significant internal organ burns



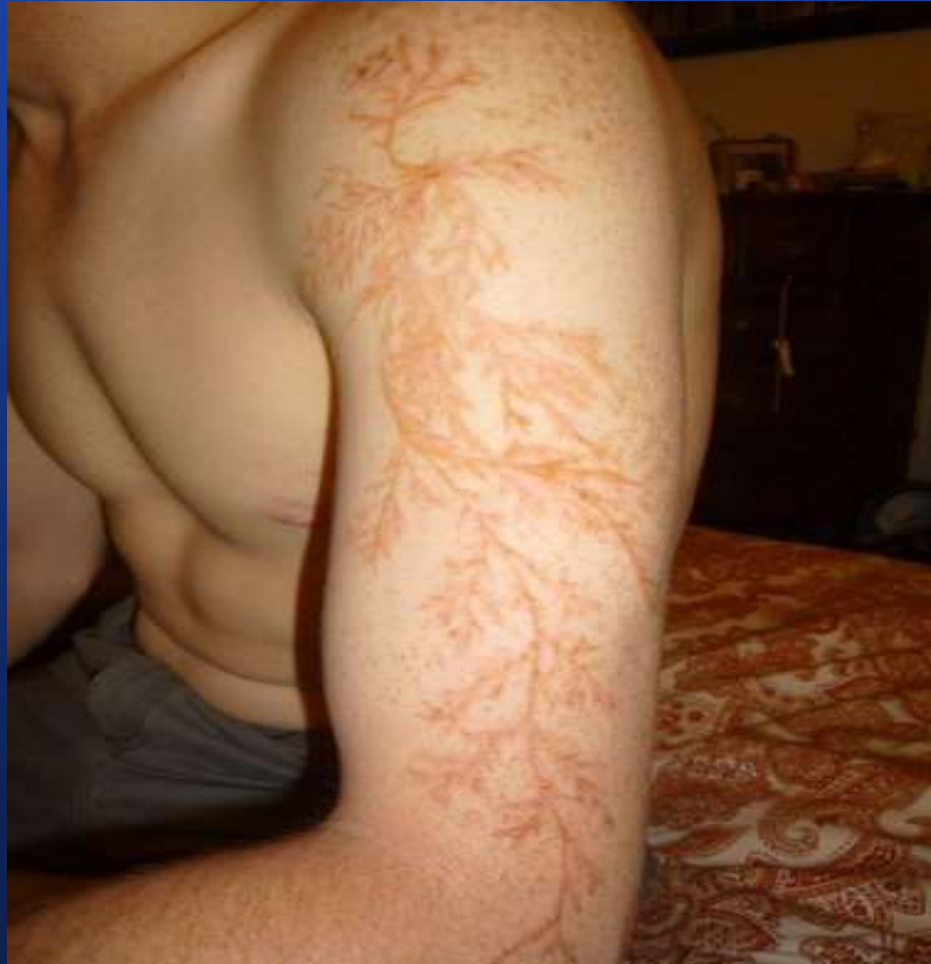Treatment of electric shock

- free the victim from the current at once (the rescuer must be protected, nonconductive materials).
- Check cardiac and respiratory function.
- Begin artificial ventilation or CPR if necessary.

LIGHTENING INJURIES



LIGHTENING INJURIES



Lightning injuries

- essentials of diagnosis:

- Can result not only in burns but also in multiorgan dysfunction
- Respiratory arrest is the most common cause of death; ventricular fibrillation and asystole are also seen in severe cases
- Management is the same as that for a person with blunt trauma

Lightning injuries

Injuries are caused by:

- Direct strike,
- Splash (i.e. from trees, buildings)
- Step voltage (spreading on ground)
- Blunt trauma from shockwaves

Lightning injuries

- Clinical findings:

- burns – fernlike pattern
- altered mental status – victims of lightning strikes are usually amnestic, disoriented or comatose
- cardiac arrest
- neurologic injuries – include traumatic brain and spinal cord injury, epidural / subdural hematomas (due to associated falls), subarachnoid hemorrhage, loss of consciousness, amnesia and confusion

Lightning injuries

- Clinical findings:

- musculoskeletal injuries – victims are thrown to the ground by tetanic muscle contractions or fall from heights, fractures of spine, ribs and extremities may occur
- eye and ear injuries – cataract, uveitis, hyphema, vitreous hemorrhage, rupture of tympanic membrane may result from acoustic and shock wave barotrauma.

Lightning injuries

Treatment:

- maintain the airway and begin cardiopulmonary resuscitation (CPR)
- traumatic injury evaluation – fractures, thoracoabdominal injury, hypothermia
- begin burn therapy and fluid replacement

Heat exhaustion

- essentials of diagnosis:

- Caused by primary water and sodium loss due to prolonged heat exposure
- Rapidly leads to heat stroke
- Symptoms of dehydration are present, but CNS symptoms are not seen
- Treatment includes rehydration and cooling.

Heat exhaustion

Signs and symptoms are non specific and include:

headache, nausea, vomiting, malaise, muscle cramps, dizziness, tachycardia, hypotension and diaphoresis.

Heat exhaustion

Treatment:

Placing the patient in cool place and giving adequate cool water and salt tablets according to the estimated amount of water and salt loss.

Heat stroke

- essentials of diagnosis:

- Extremely high body temp (41°C or more) causing altered mental status (ranging from confusion to coma), cardiovascular collapse and multiorgan dysfunction
- Rhabdomyolysis, acute renal failure and severe hepatic damage occur
- Treatment is rapid reduction in body temp.

Heat stroke

Treatment:

- Act quickly to prevent further damage
- Maintain adequate airway and ventilation
- Reduce body temp – as first-aid place the patient in shady cool place, remove clothing and sprinkle body with water and cool by fanning
- Maintenance of adequate urine output.

Heat stroke

Hospitalize all patients with body temp. 41°C or more for treatment of possible complications (DIC, renal failure, cardiac arrhythmias, myocardial infarction, coma).

Systemic hypothermia

- essentials of diagnosis:

- mild 34 – 36°C
- moderate 30-34°C
- severe - below 30°C.

Patient may appear dead at that stage with fixed dilated pupils, loss of reflexes and coma.

No one is dead until he is „warm and dead”.

Systemic hypothermia

Complications:

metabolic acidosis, pneumonia, pancreatitis,
renal failure,

ventricular fibrillation and cardiac arrest may
occur during rewarming

Cold injury of extremities

- essentials of diagnosis:

- Tissue injury or death is caused by ischemia and thrombosis in capillaries or by formation of ice in the tissues
- Treatment of frostbite or chilblains depends on the severity of skin injury and includes rewarming by both passive and active measures

Cold injury of extremities

Exposure of the extremities to cold produces intense vasoconstriction.

When skin temp. falls to:

- 25°C → tissue metabolism is slowed
- 10°C – 4°C → freezing occurs.

Cold injury of extremities

Chilblains

– less severe from cold injury than frostbite;
red, pruritic skin lesions on face and extremities
caused by exposure to cold.

May be associated oedema and blisters.

Treatment:

Elevate the affected part on pillow and allow it to
warm at room temp.

Cold injury of extremities

Frostbites

- injury of the tissue due to freezing;
tissue is blue-white, hard, cool and insensitive.
Profound edema, hemorrhagic blisters,
necrosis and gangrene may occur.

Cold injury of extremities

Frostbites treatment:

- Rewarming in hospital conditions
- Protection of the injured part from further trauma
- Prevent infection and administer tetanus prophylaxis
- Surgical amputation of death tissues
- Early HBO may decrease tissue loss.

High-altitude sickness

- spectrum of diseases that affect unacclimatized people in the relative hypoxia of altitude



Acute mountain sickness (AMS) – essentials of diagnosis:

- headache with some related symptoms (anorexia, nausea, vomiting, fatigue, weakness, insomnia)
- treatment is descent, oxygen and antiemetics
- if descent is not possible, dexamethason or acetazolamide can be used to aid acclimatization

Acute mountain sickness (AMS) – essentials of diagnosis:

- self-limited but may progress to high-altitude cerebral oedema or high-altitude pulmonary oedema (onset 1h-3days)

Acute mountain sickness (AMS)

Treatment:

- rest, allow physiologic acclimatization before further ascent
- NSAIDs and antiemetics
- acetazolamide 125-250 mg is effective in AMS prophylaxis, starting 1 day before ascent, continuing to day 4
- graded ascents of 600m / day with rest allow sufficient acclimatization, preventing AMS.

Acute high-altitude pulmonary oedema

– essentials of diagnosis:

- noncardiogenic pulmonary oedema due to rapid ascent above 2400m
- cough and dyspnea on exertion lead to pink, frothy sputum and respiratory distress
- chest X-ray findings show patchy infiltrates but normal heart size
- treatment is rapid descent, continuous positive-pressure ventilation, oxygen, nifedipine

High-altitude cerebral oedema - essentials of diagnosis:

- due to rapid ascent to altitudes above 2400m
- headache, ataxia, papilledema, global encephalopathy
- treatment is immediate descent, oxygen, dexamethasone



Bees and wasp sting

- essentials of diagnosis:

- Hymenoptera envenomation usually result in urticarial lesion at the site of the sting;
- more severe reactions – anaphylaxis, multiorgan dysfunction
- treatment – oral pain control, tetanus prophylaxis, diphenhydramine
- in severe reactions – airway management, vasopressors, dialysis may be needed

Carbon Monoxide poisoning

- essentials of diagnosis:

- colorless, odorless gas produced by incomplete combustion of organic materials from fires, gas heaters, motor vehicle engines, and other sources.
- binds to hemoglobine forming carboxyhemoglobin (HbCO) which cannot transport oxygen
- blood may appear cherry-red

HbCO level correlate with symptoms

HbCO level :

< 5% is normal,

5-10 % causes slight headache,

10-30 % - severe headache,

30-50 % - tachycardia, confusion, lethargy,
collapse,

50-70 % - coma, death.

Carbon Monoxide poisoning - complications

- myocardial infarction,
- delayed parkinsonism,
- memory loss,
- personality changes.

Carbon monoxide poisoning is the leading cause of toxic death.

Carbon Monoxide poisoning

- treatment:

- immediately administer high-flow oxygen (continue until HbCO level returns to normal)
- Hyperbaric oxygen treatment for the:
 - pregnant women (due to increased sensitivity of fetal Hb),
 - patients with HbCO > 25%,
 - patients with loss of consciousness, metabolic acidosis or myocardial ischemia.

