

Joanna Jakubaszko – Jabłońska

OCULAR TRAUMA



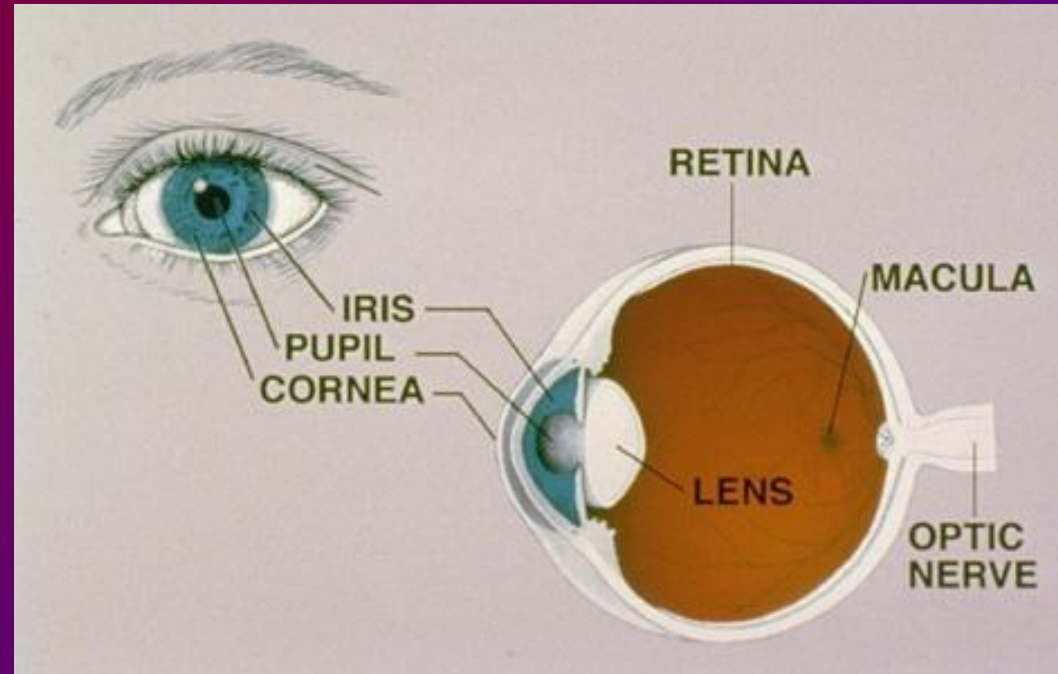
**Polskie Towarzystwo
Medycyny Ratunkowej**

**Polish Society for
Emergency Medicine**

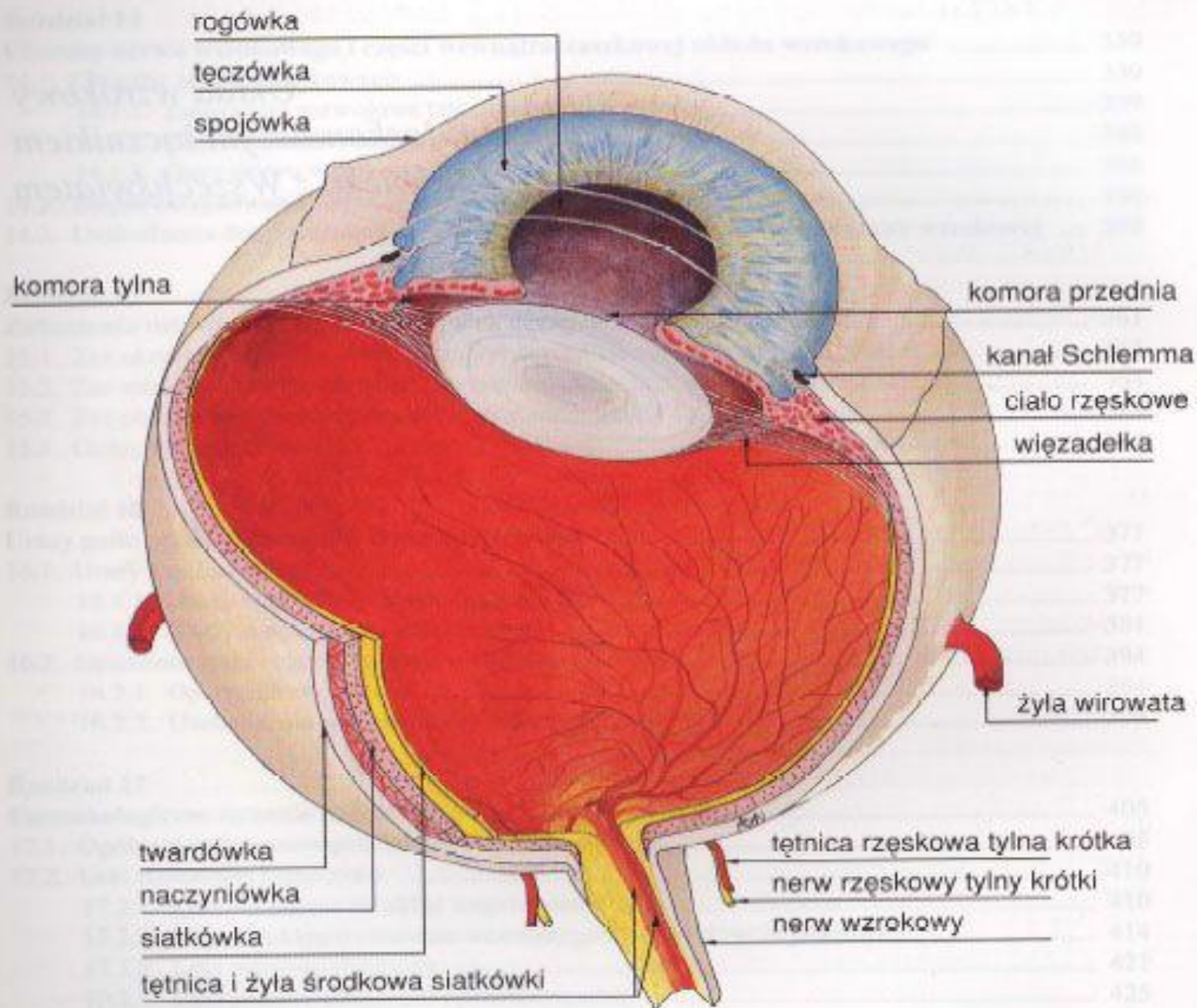
**Chair of Emergency Medicine
Wroclaw Medical University**

Ocular trauma

- Blunt trauma
- Penetrating injury
- Foreign body
- Burns



All kinds of injury may threaten vision directly or indirectly.



Important factors influencing final results of eye trauma treatment and functional vision:

- First aid at site of accident
- The way of examination
- Duration of transport to the hospital

Life supporting action according to multiorgan injury victim may not be a reason of neglecting of injured eyes protection or additional ocular trauma.

After injury:

- Ask about circumstances of accident
- First estimation of injured eye
- Examination of position and mobility of eyeball
- Examination of vision / light perception
- Imaging (RTG, USG, CT)

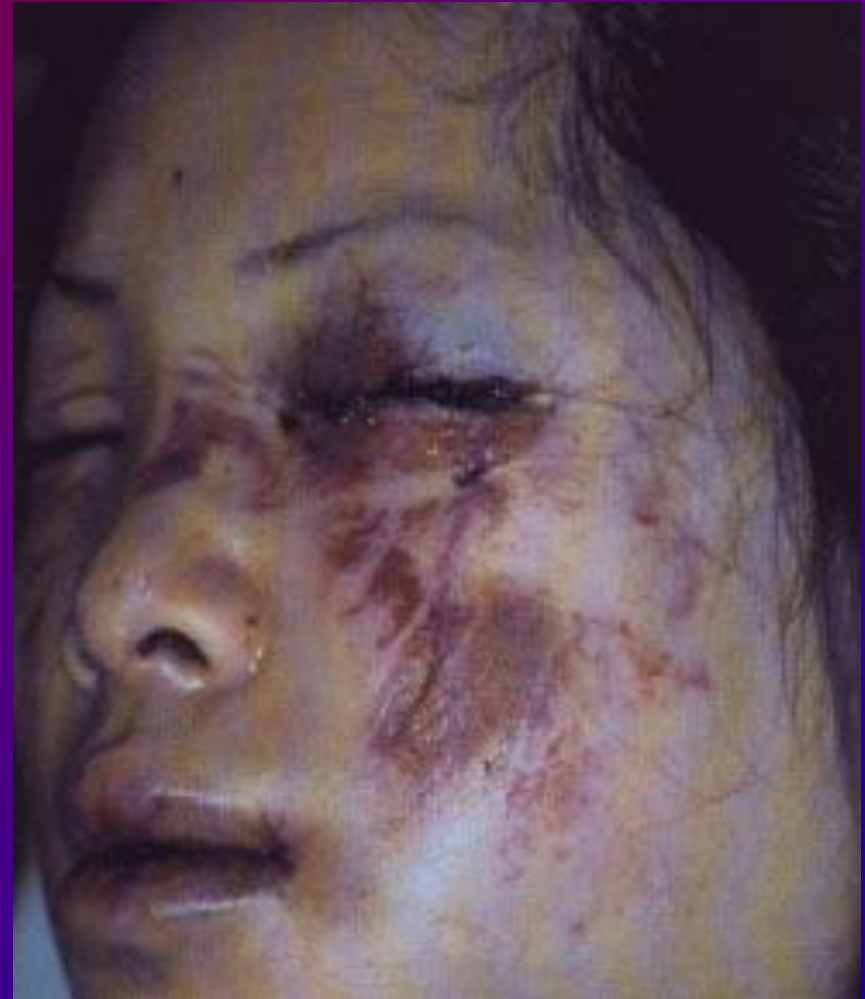First estimation of vision (V)

- Counting fingers from 5m
- Counting fingers from 1m
- Counting fingers in front of the eye
- Hand movement
- Light perception – with or without localization

Remember to cover another eye!

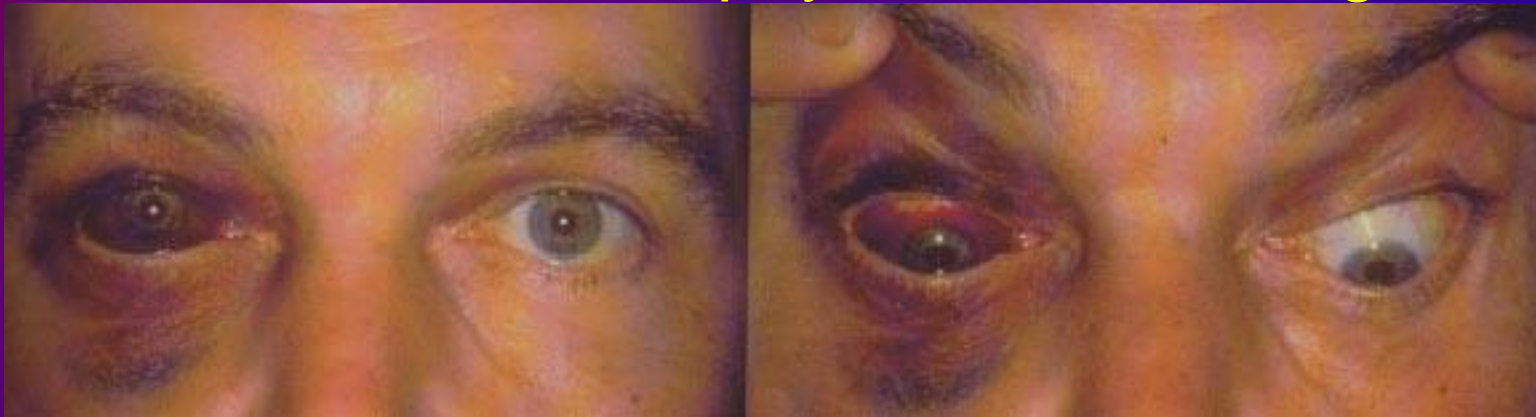Mechanical trauma of the orbit

- injury of soft tissue and facial bones fractures
- diagnostic and therapeutic management depends from injury extent

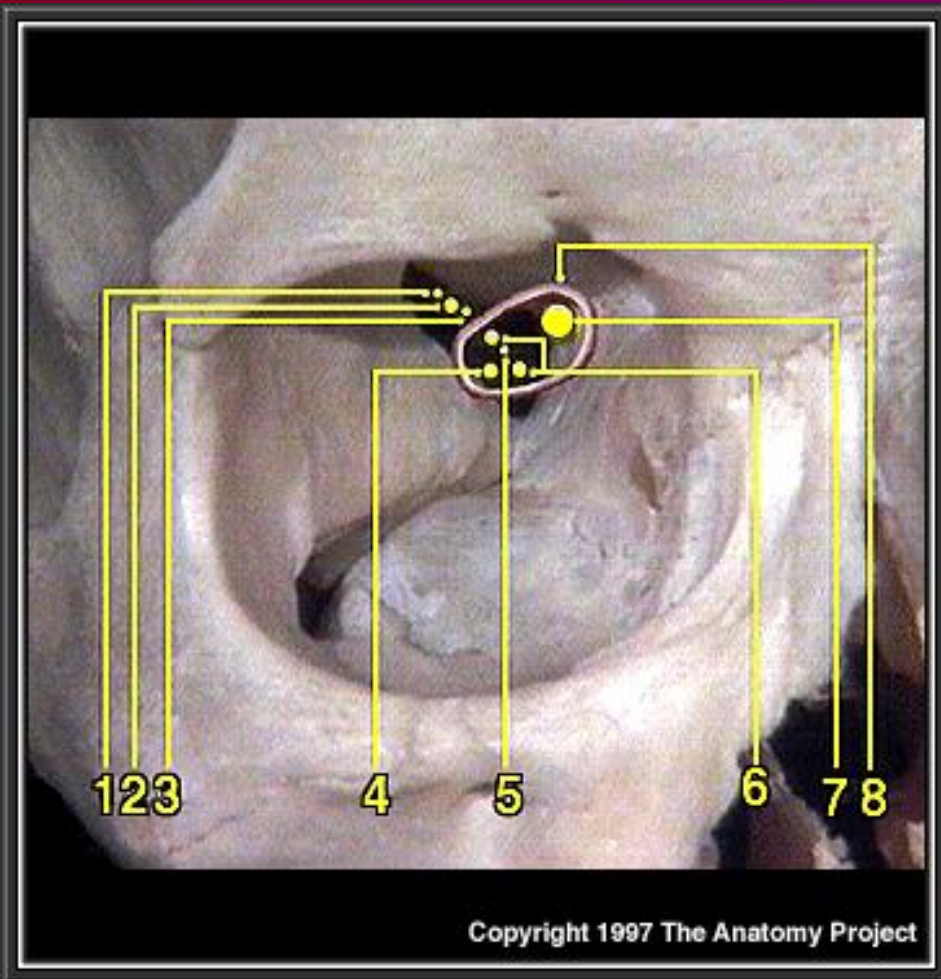


Orbit contusion

- Periorbital haematoma, subconjunctival ecchymoses
- Injury of eye lids
- Intraorbital haematoma - with/without eyeball displacement, disorders of eye mobility
- Ethmoidal fracture
 - orbital emphysema– exophthalmus, diplopia
 - subcutaneous emphysema– crackling



Superior orbital fissure



1. Lacrimal nerve (V)
2. Frontal nerve (V)
3. Trochlear nerve (IV)
4. Abducent nerve (VI)
5. Nasociliary nerve (V)
6. Superior & inferior divisions of the oculomotor nerve (III)
7. Optic nerve (II)
8. Common tendinous ring

Damage of superior orbital fissure— nn. III, IV, V₁, VI, orbital superior vein

Superior orbital fissure syndrome

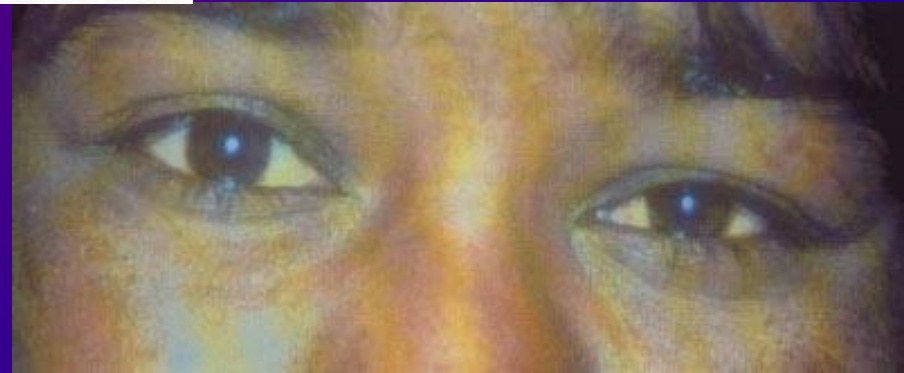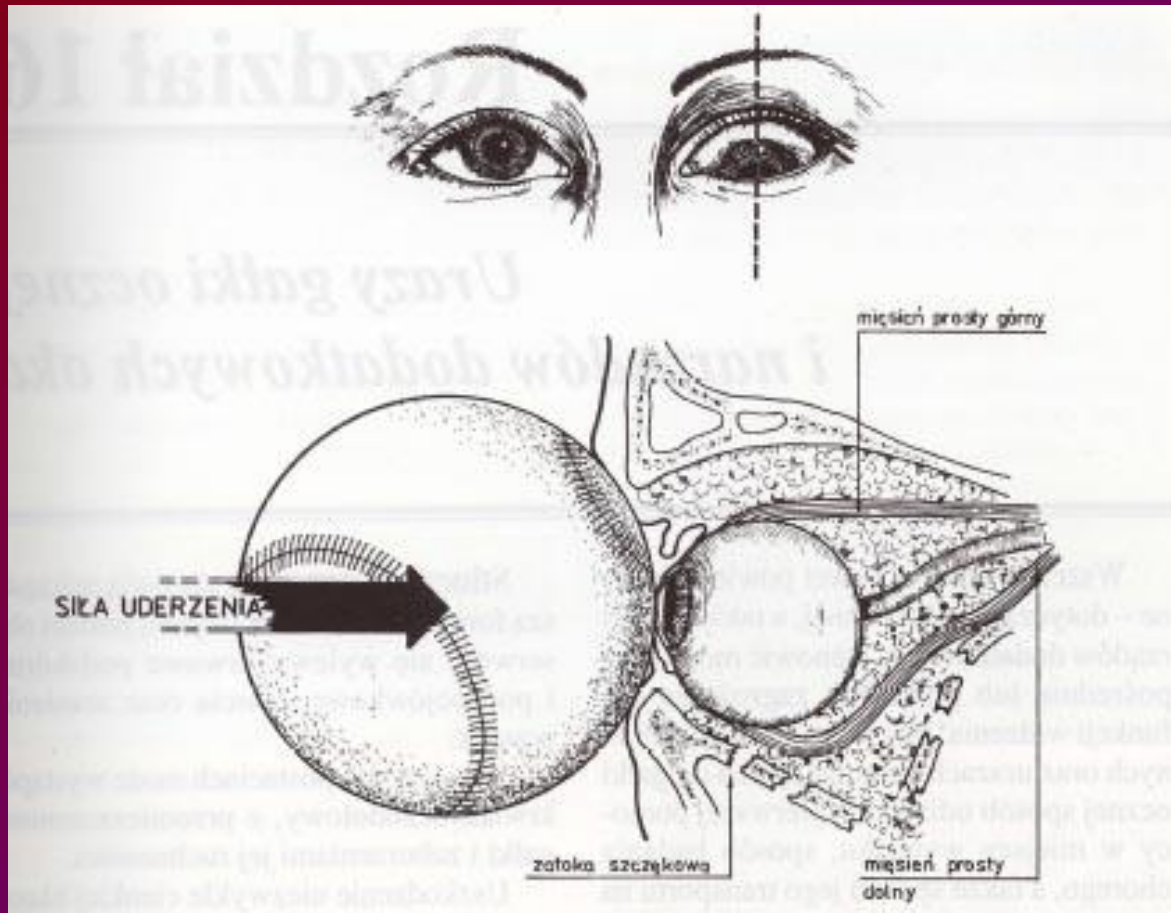
- ptosis
- exotropia
- Dilatation of pupil (mydriasis)
- Anaesthesia – skin of forehead, upper lid, cornea
- Orbital venostasis - exophthalmus

Orbital apex syndrome

– as above + optic nerve and ophthalmic artery damage – sudden loss of vision

If optic nerve is compressed urgent surgical decompression is necessary

Blow-out fracture of the orbit

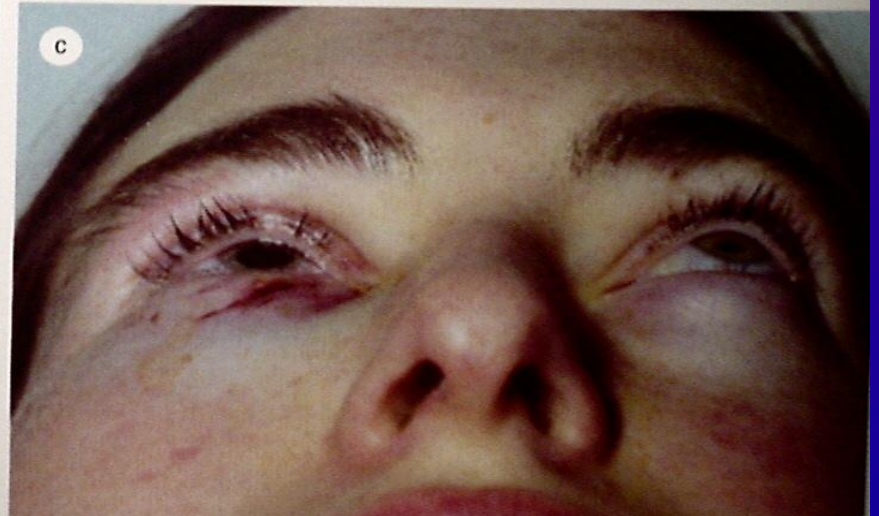
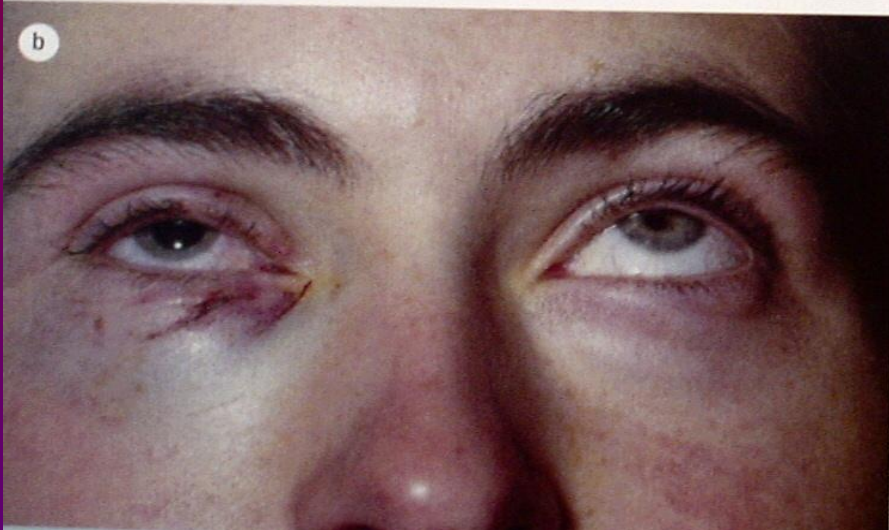
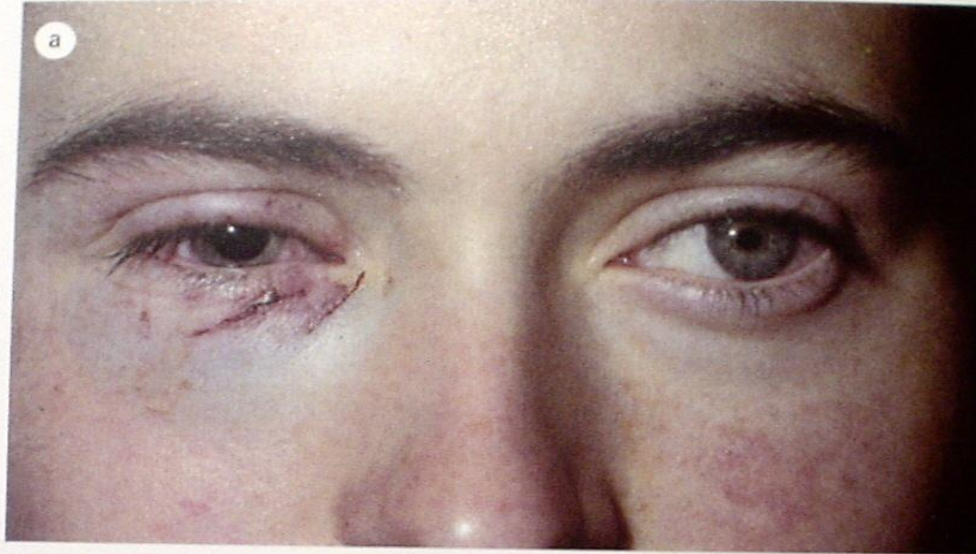Blow-out fracture of the orbit

- involves orbital floor usually with mechanical entrapment within the fracture of inferior rectus muscle
- caused by a sudden increase in orbital pressure by striking object over 5cm in diameter (airbag, tennis ball)
- Infraorbital nerve anaesthesia (lower lid, cheek, side of nose, upper lip and teeth)
- inferior displacement of the globe
- Defective elevation of eye
- diplopia

Management: ophthalmic examination, MRI / CT,
Surgical treatment.

Blow out



Intraorbital foreign body

- Circumstances of the accident,
- RTG, USG, MRI
- Revision of entrance of wound
- Possible complications: phlegmon of the orbit, intracranial infection

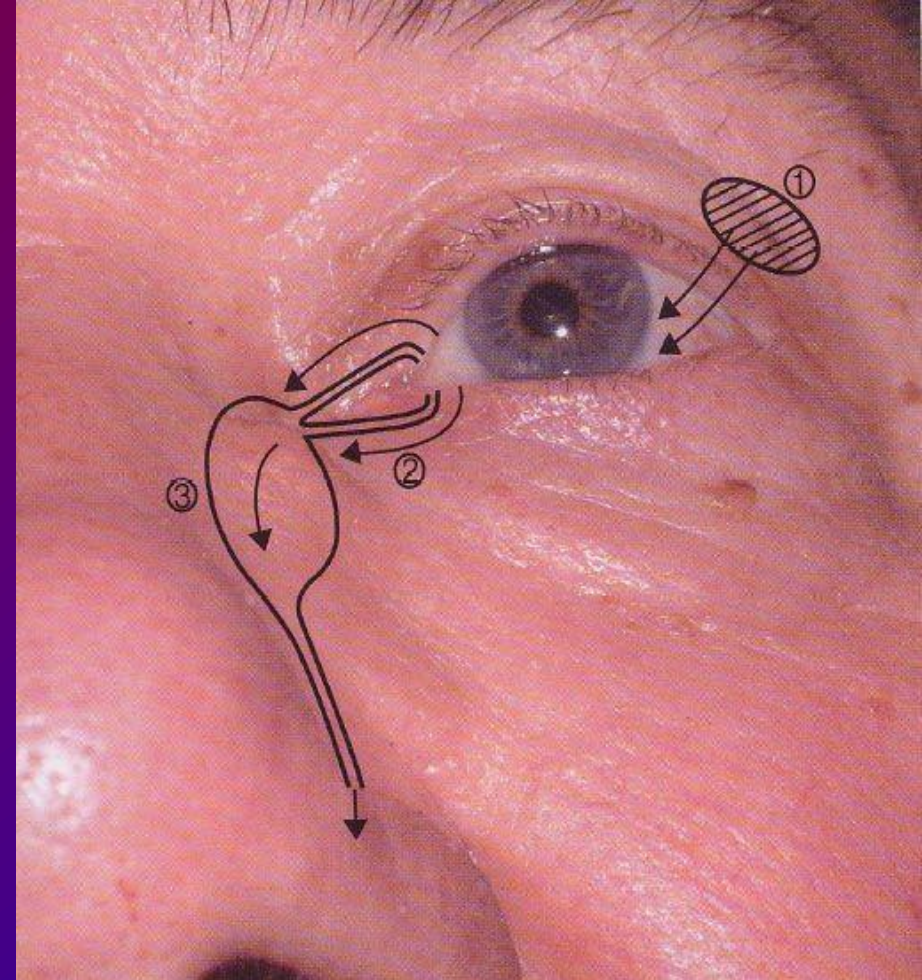
Lids injury

- Precise surgical treatment is necessary.

Canalicular lacerations should be repaired within 24h.

Improper management may cause complications:

- improper position of eye lids,
- Defective closure of lids – corneal ulcer
- Lacrimal obstruction



Mechanical trauma of the globe

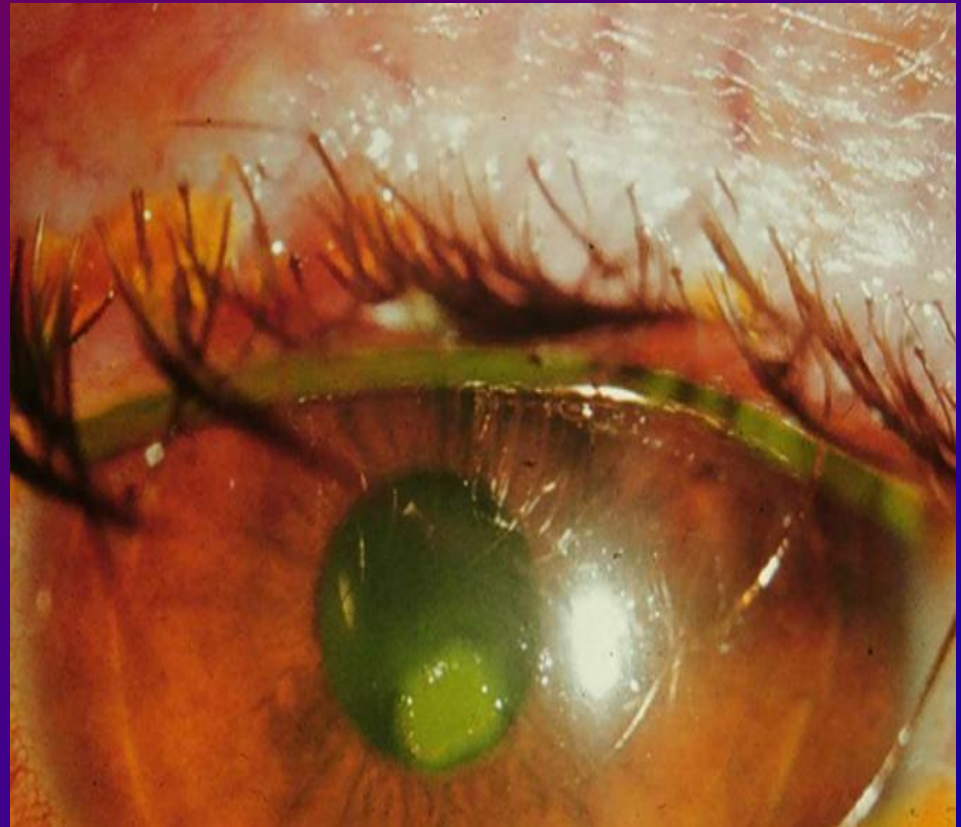
- Blunt trauma
- Acute injury – superficial and penetrating
- Foreign body

Results:

- transient or permanent ocular lesion,
- direct or indirect (late) consequences for vision

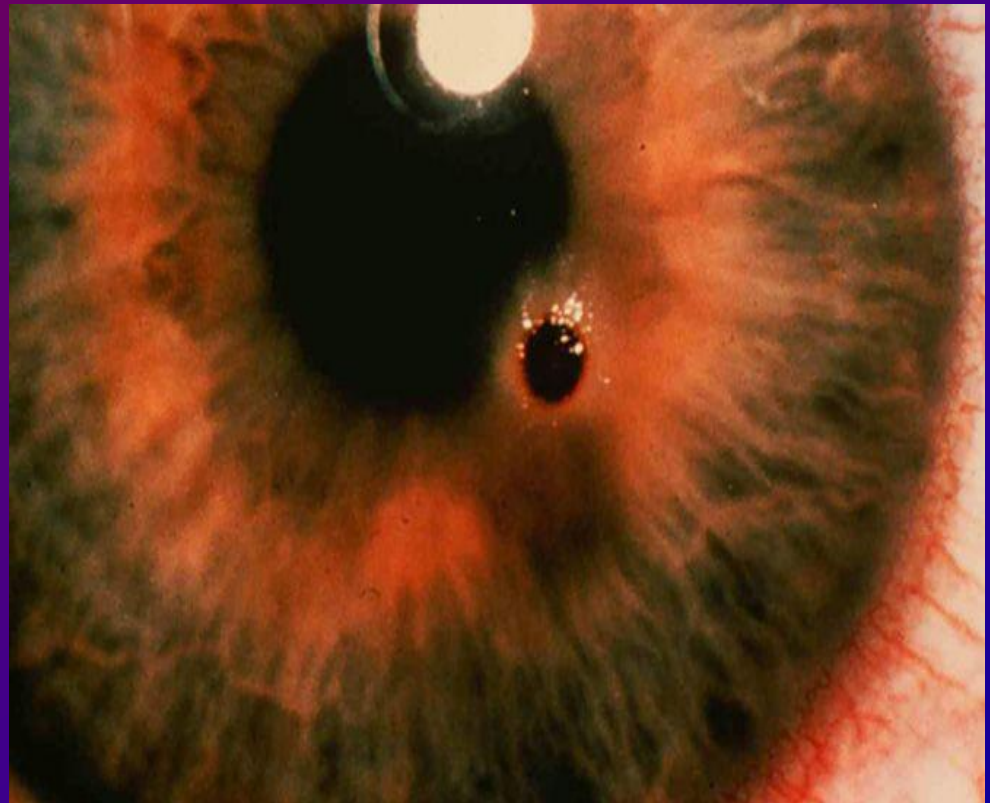
Erosion of corneal epithelium

- Superficial injury (by hand, twig, etc.) or presence of foreign body under upper lid
- Strong pain, blepharospasmus, lacrimation
- Positive fluoresceine test



Superficial foreign body

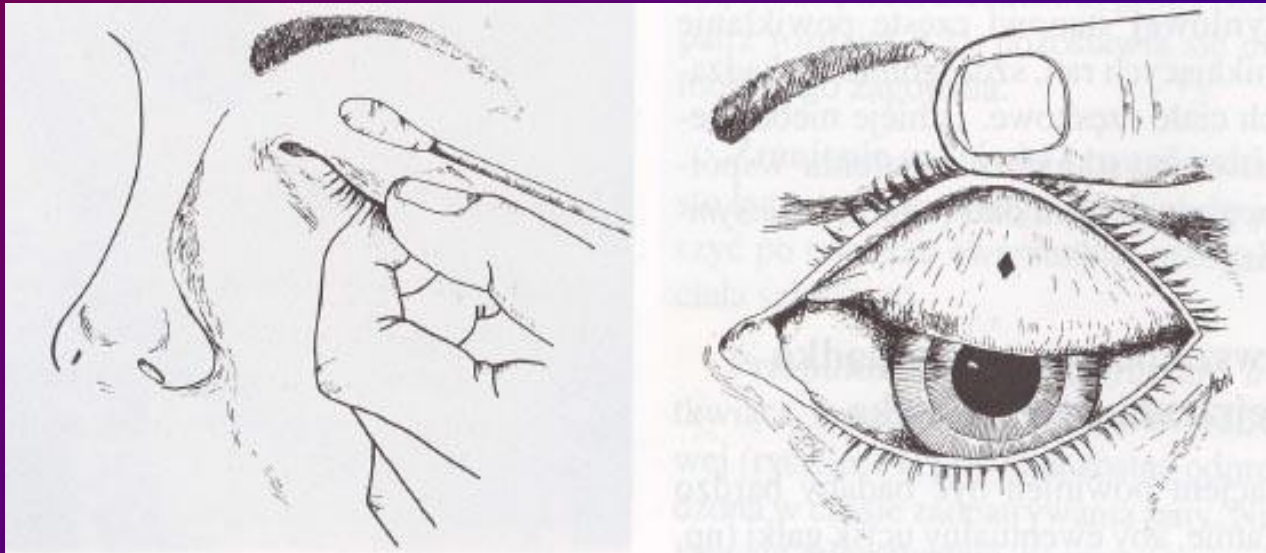
- In conjunctival sac
- Under upper lid
- on the cornea
- **Symptoms:** strong pain, red eye, lacrimation, photophobia



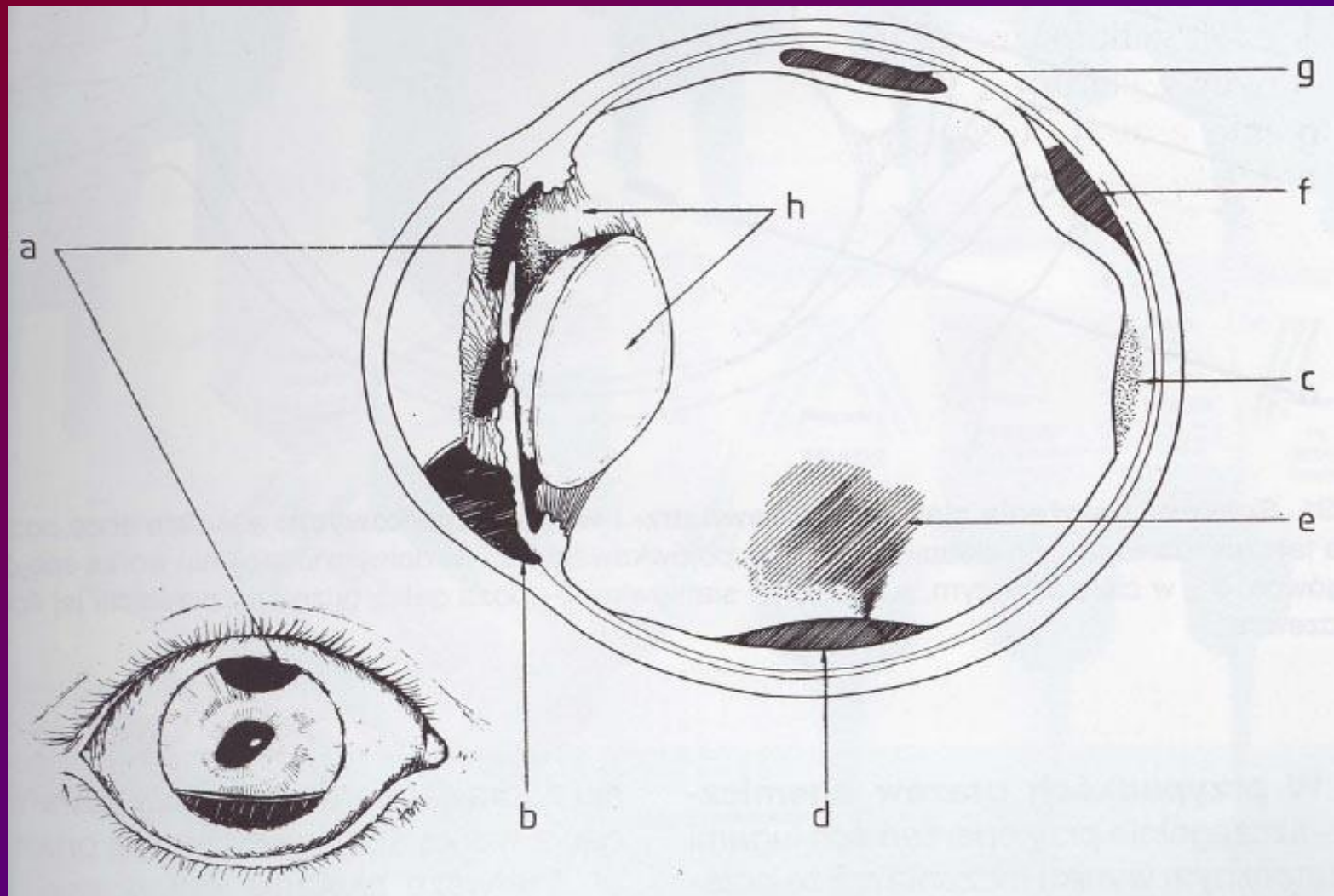
Corneal erosion / superficial foreign body

- management:
- anamnesis
- Turning upper lid and removing foreign body
- Antibiotic ointment, dressing for 24h

Contamination of wound is a risk factor of infection.

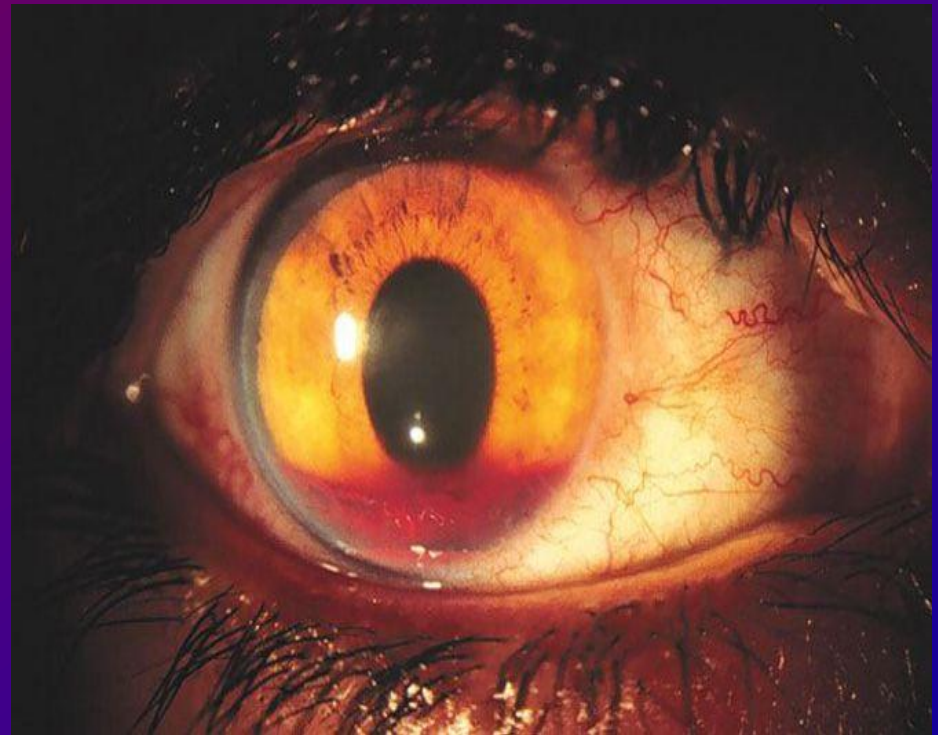


Blunt trauma of the eye



Haematoma of the anterior chamber

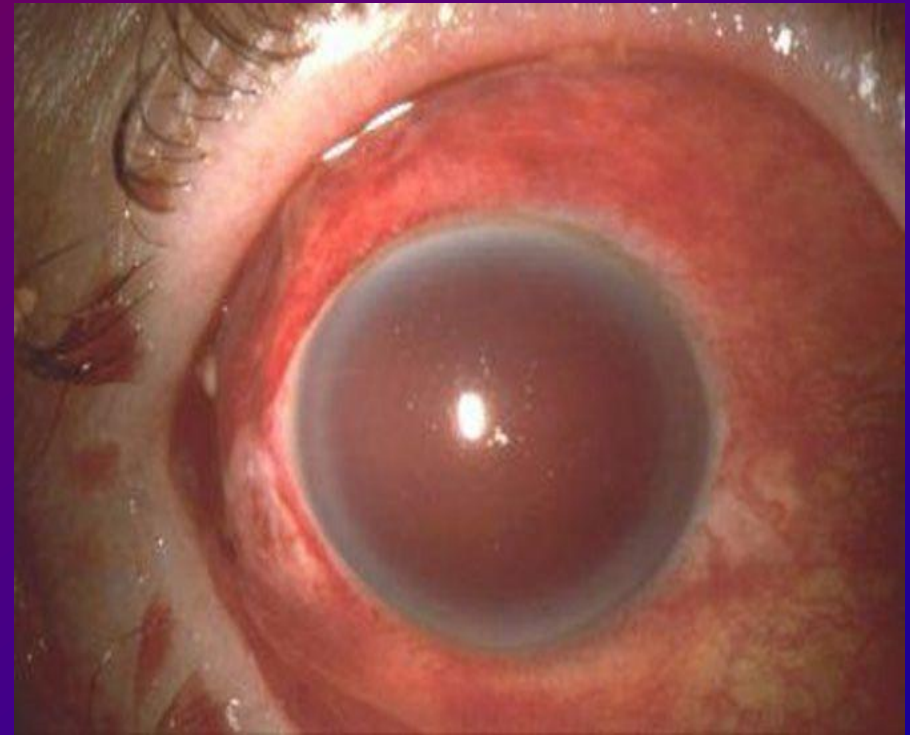
- Usually after strong blunt trauma (egz. cork from champagne bottle)
- Pain, vision loss
- Small amount of blood - self resorbtion
- Big amount of blood– may result from severe intraocular demage, possible secondary glaucoma,



Haematoma of the anterior chamber

-management:

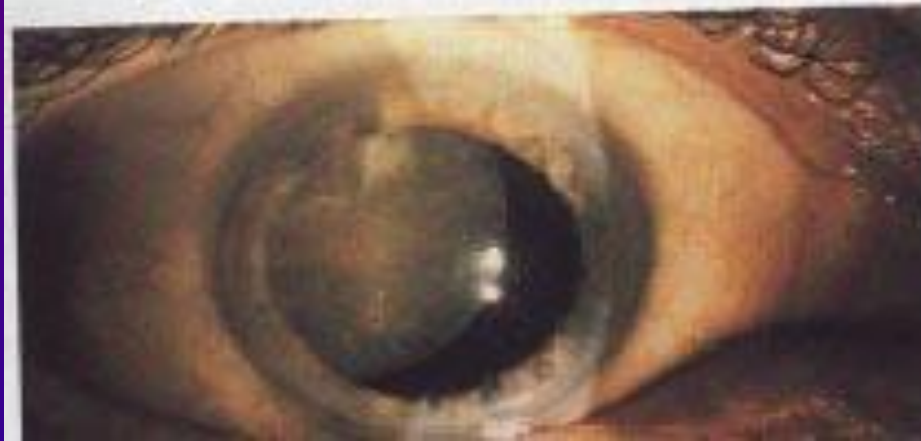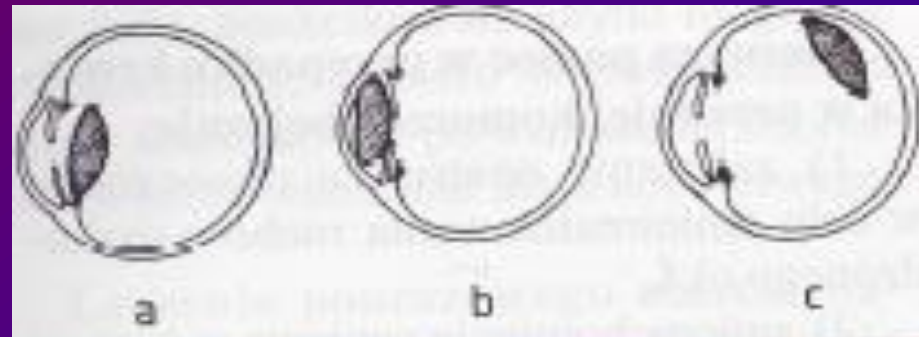
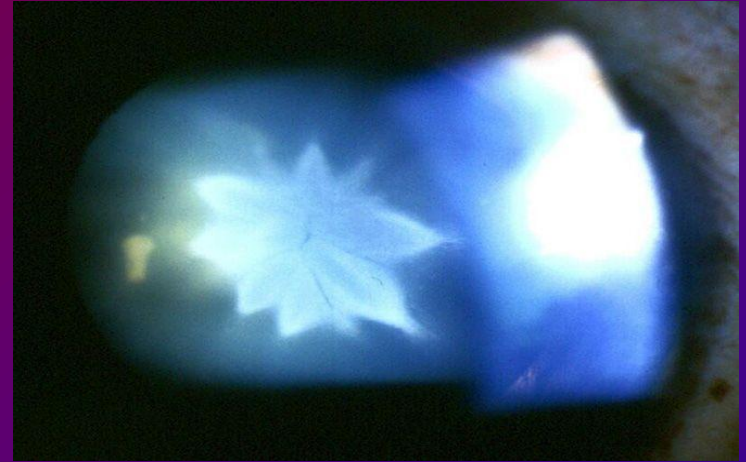
- Dressing on both eyes to minimize movement of injured eye,
- Vertical position of patient's head
- Hospital management – due to further examination results



Damage of lens due to blunt trauma

- Post-traumatic cataract
- subluxatio / luxatio of the lens – to anterior or posterior chamber of the eye

Treatment: surgical



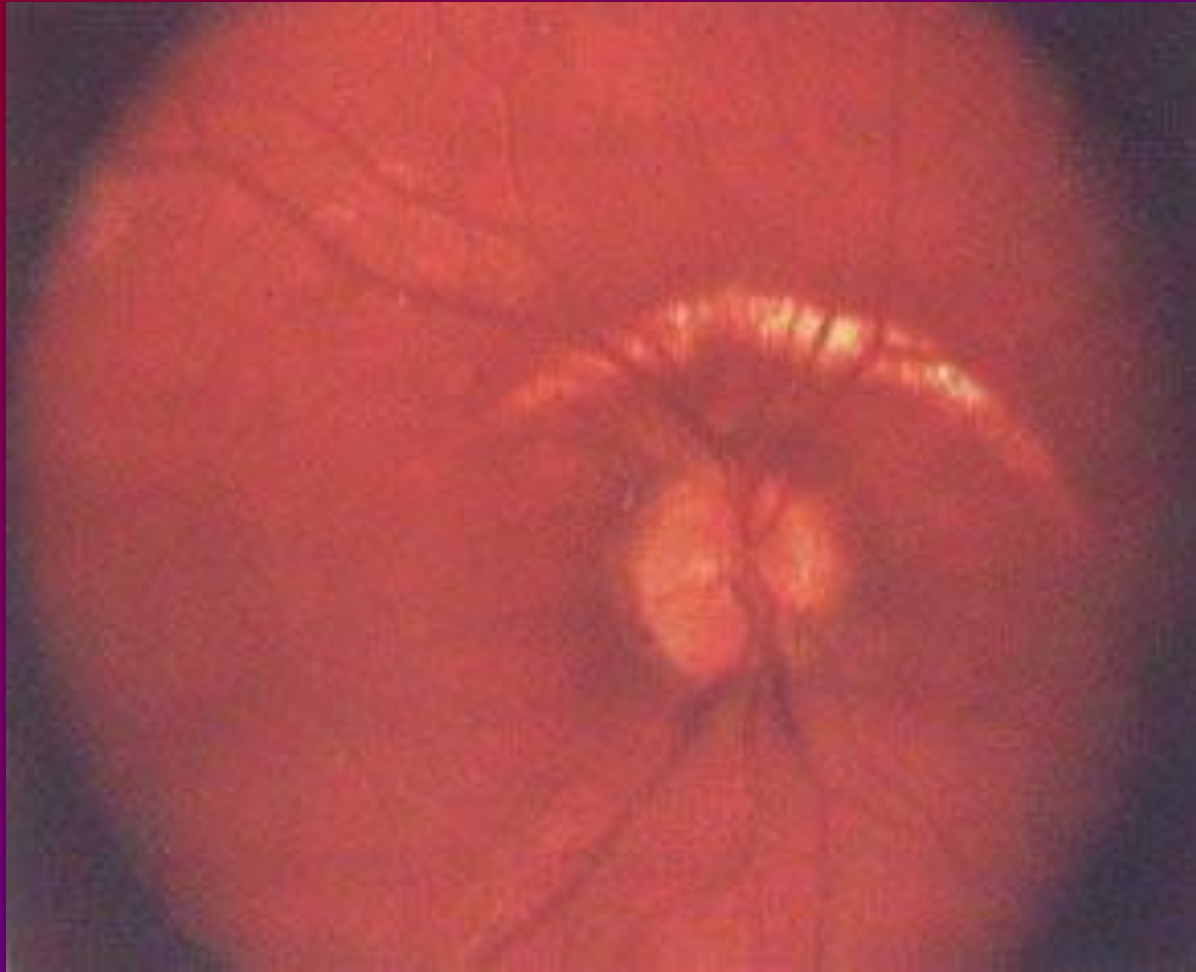
Rupture of the eye ball – after blunt trauma

Symptoms:

- Oedema and subconjunctival haematoma ,
- Sudden loss of vision (blood in anterior chamber / in vitreous body)
- *Soft eyeball!* – significant decrease of intraocular pressure
- Rupture in anterior segment– often under rectus muscle attachment, conjunctiva may be not damaged.
- Rupture in posterior segment– usually near optic nerve.

Management:

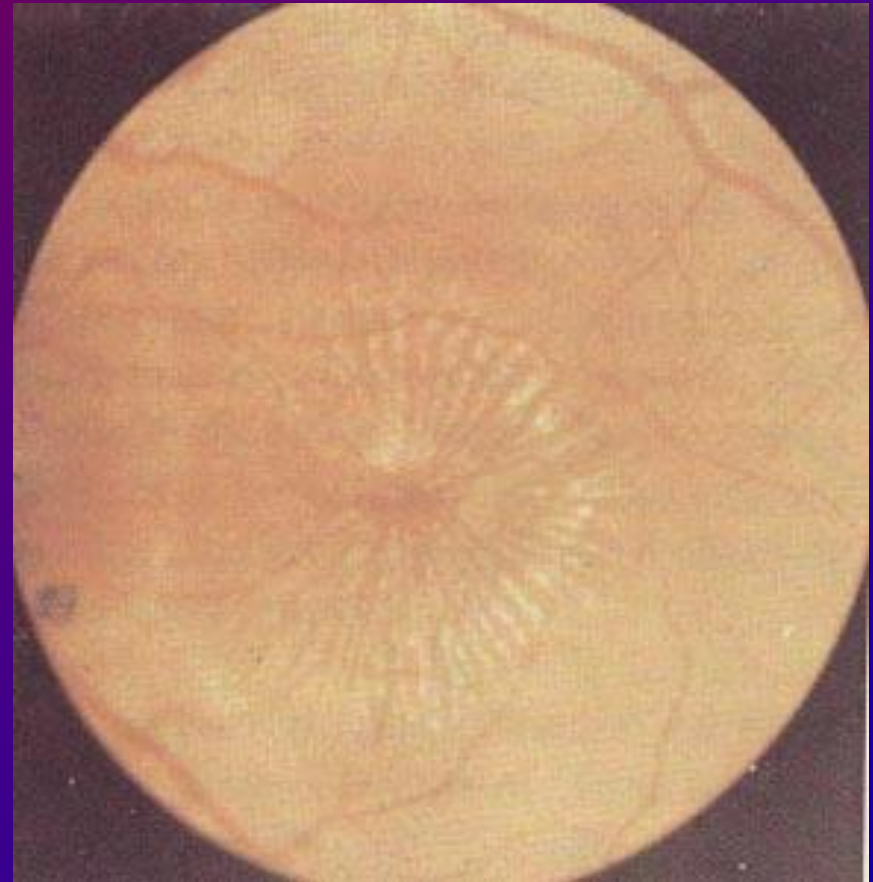
- Protection of eye from pressure
- Surgical treatment



Post-traumatic rupture of choroid

Commotio (oedema) of the retina

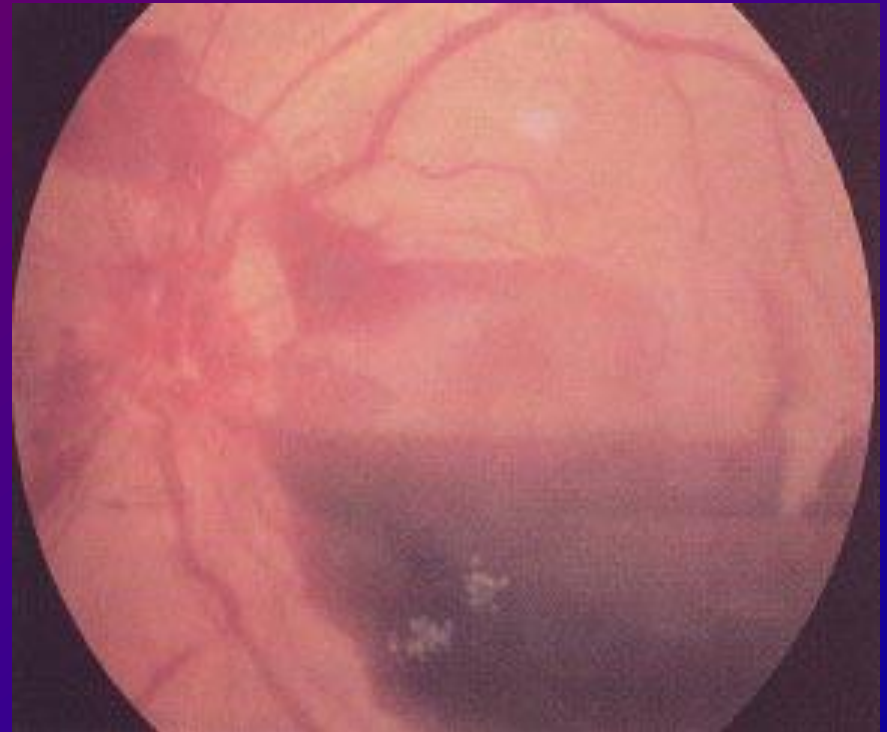
- After head trauma or influence of explosion
- Results from paralysis of tiny retinal vessels
- Pallor of retina
- Decrease of visual acuity
- Self-improvement in few weeks



Terson syndrome

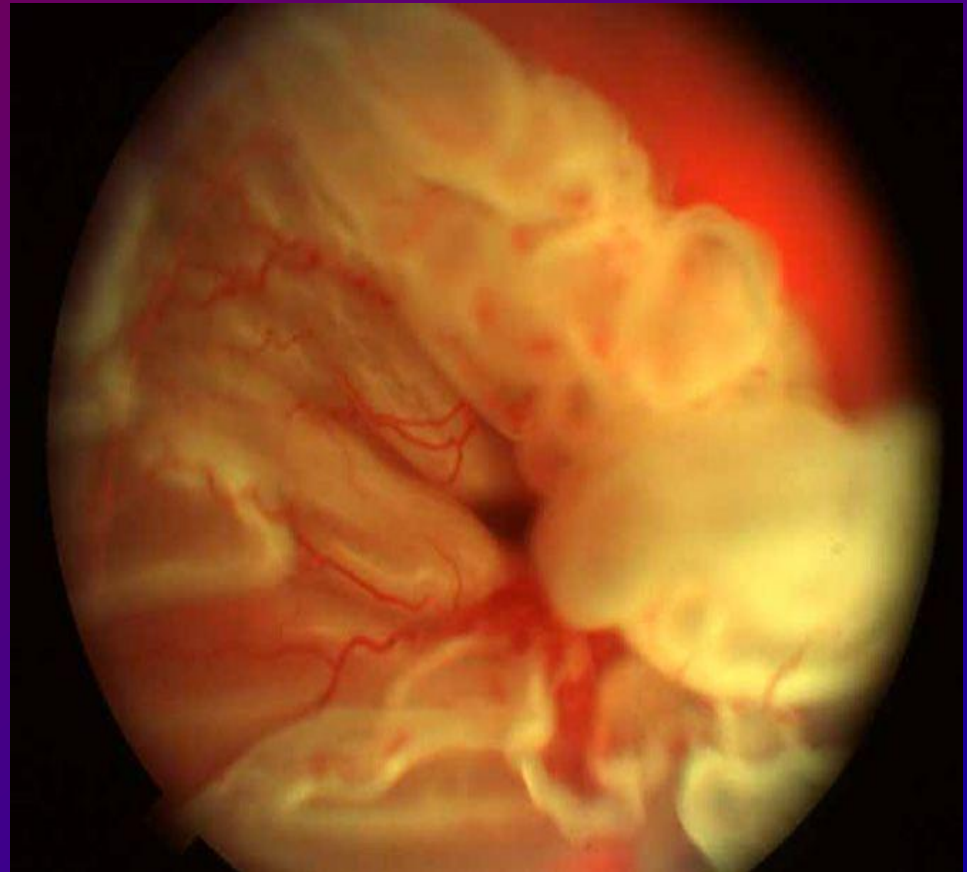- due to acute subarachnoidal bleeding

- Mechanism: acute increase of intracranial pressure cause rupture of tiny retinal vessels
- Preretinal haemorrhages or in vitreous body
- Usually self resorbtion – in few months

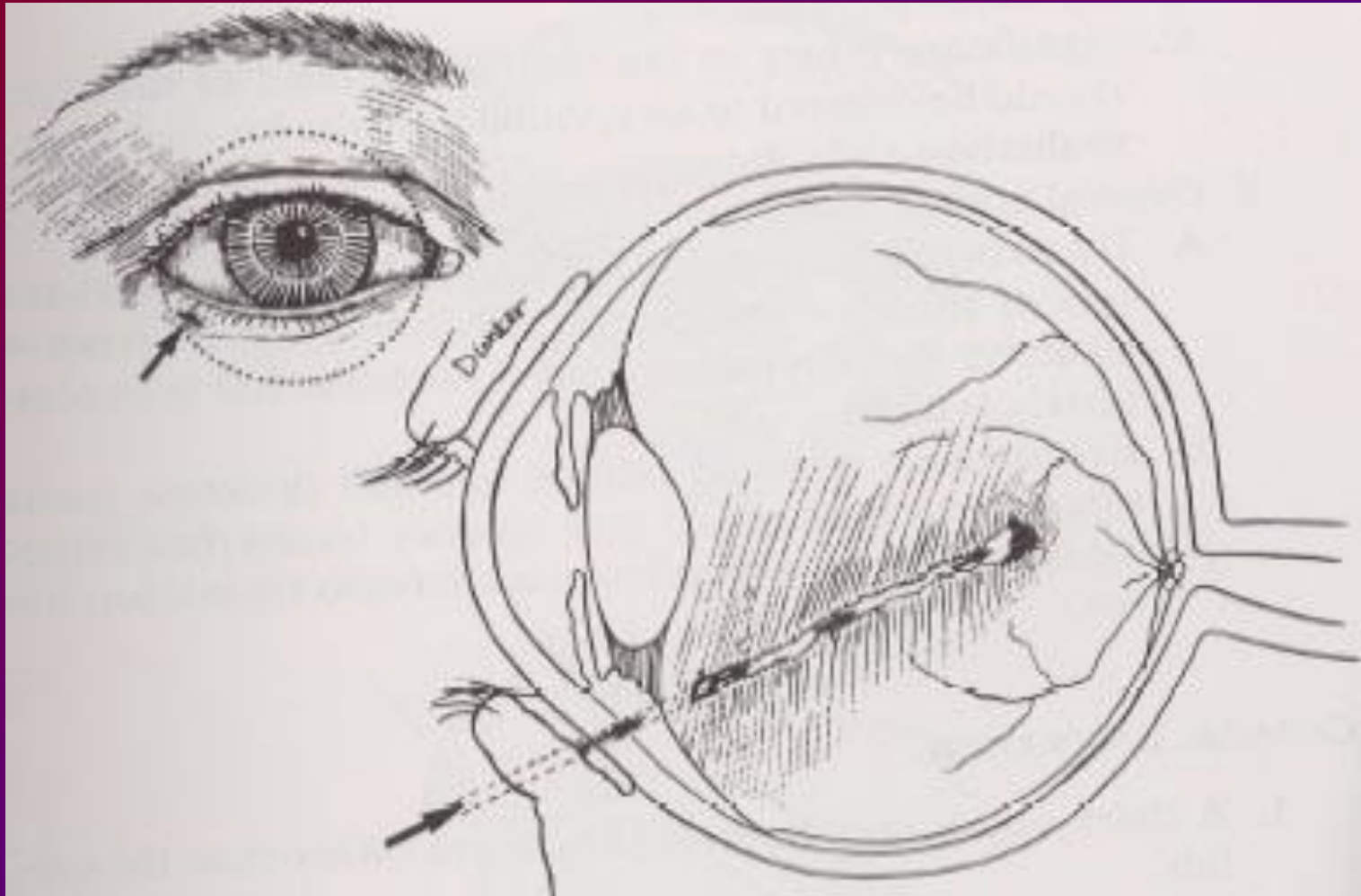


Retinal detachment

- After blunt trauma
- More often in myopic eyes
- Decrease of vision
- Painless
- Treatment: surgical

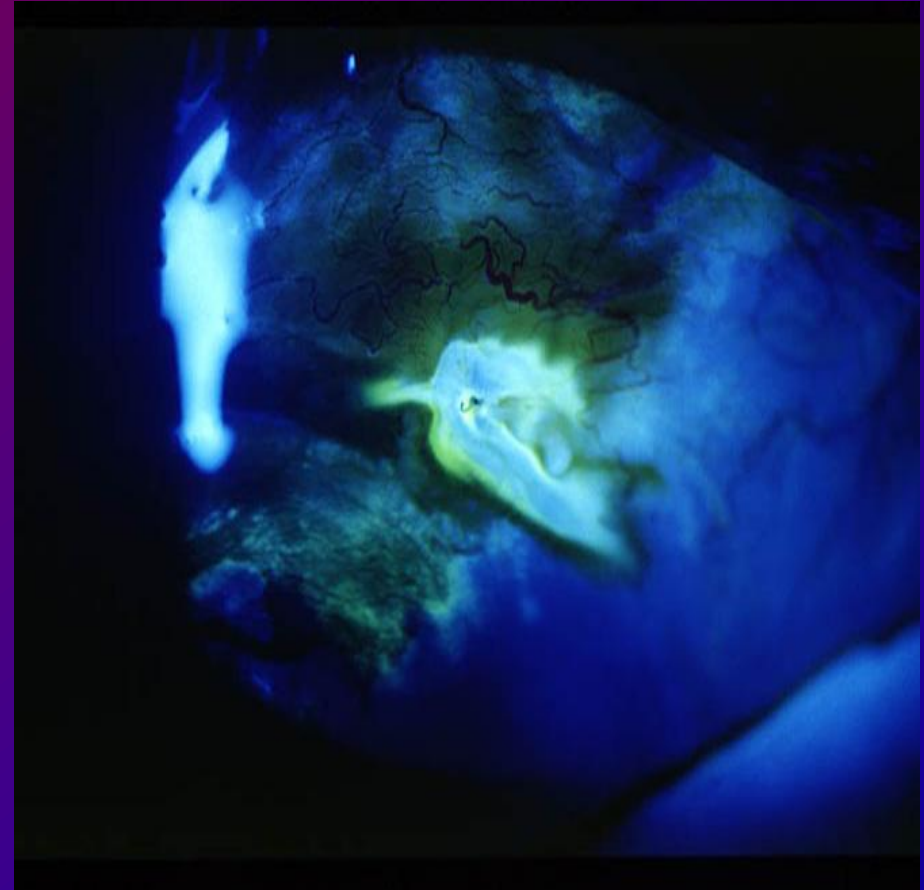


Acute injury of eyeball



Penetrating injury of cornea or conjunctiva and sclera

- Ask about circumstances of accident
- *Seidel test*
 - Topical fluorescein to check leaking of aqueous humor from the wound



Penetrating injury

postraumatic cataract - when the lens is injured

- opacities and swelling of lens,
- displacement of damaged lens to other compartments of the globe – complications: uveitis, secondary glaucoma

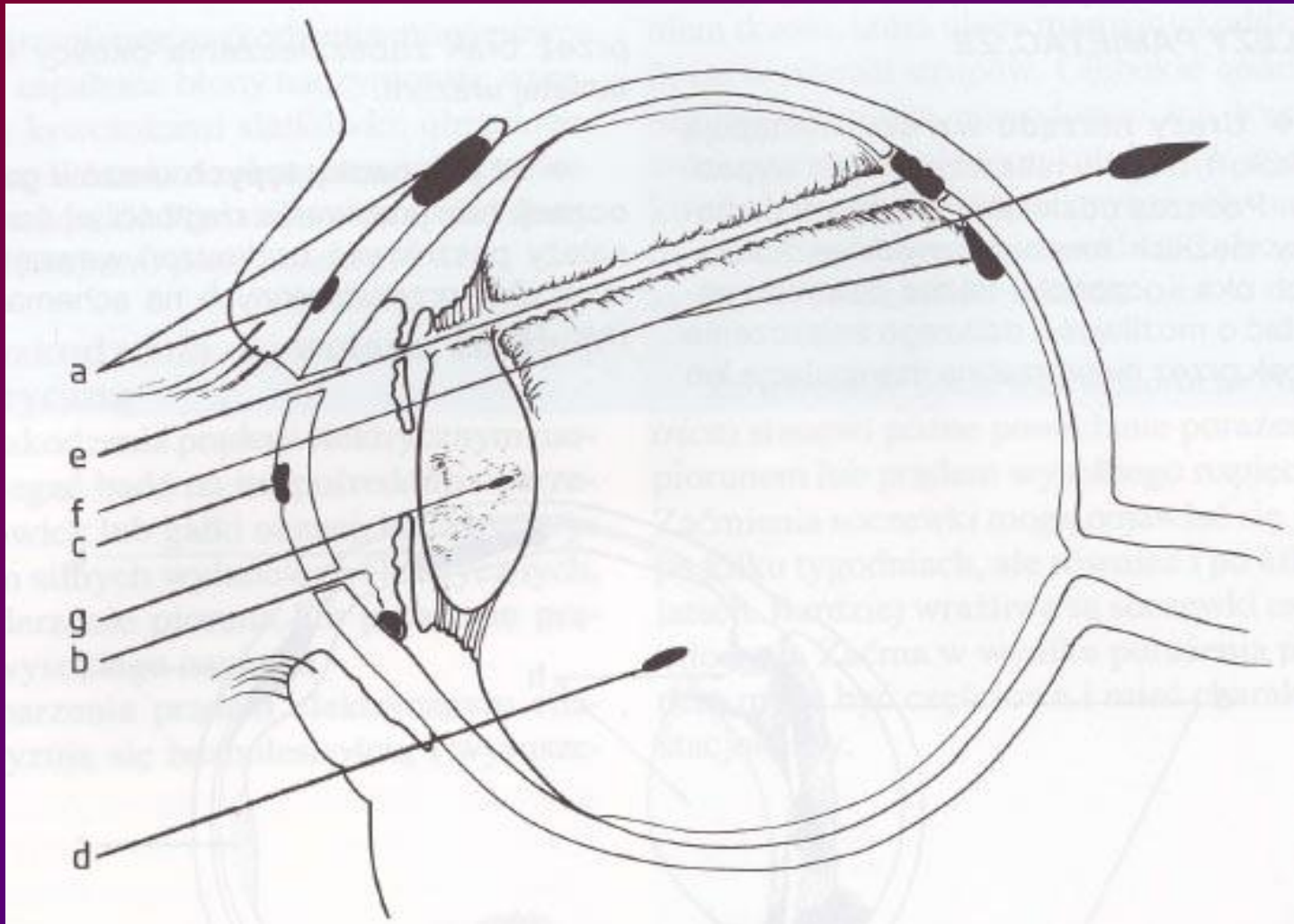
Management in case of penetrating injury of the eye

- Very careful examination - not to press the eye
- Pressure protecting dressing
- Do not administer any eye drops or ointment to the injured eye – they may penetrate the wound and cause intraocular infection
- Ophthalmological emergency room

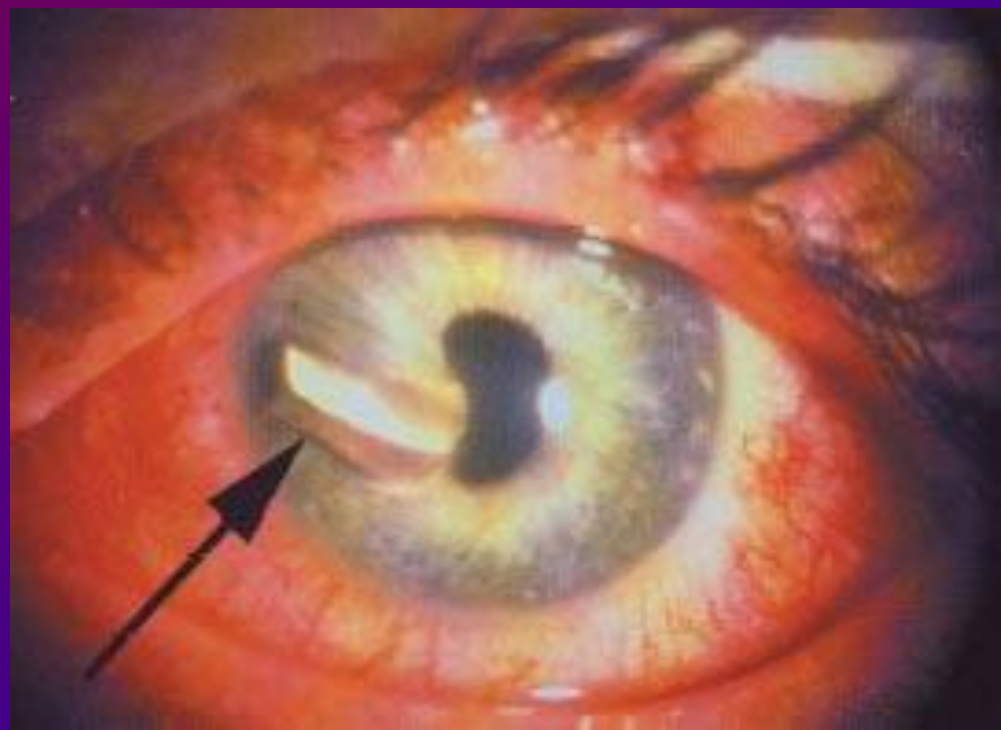
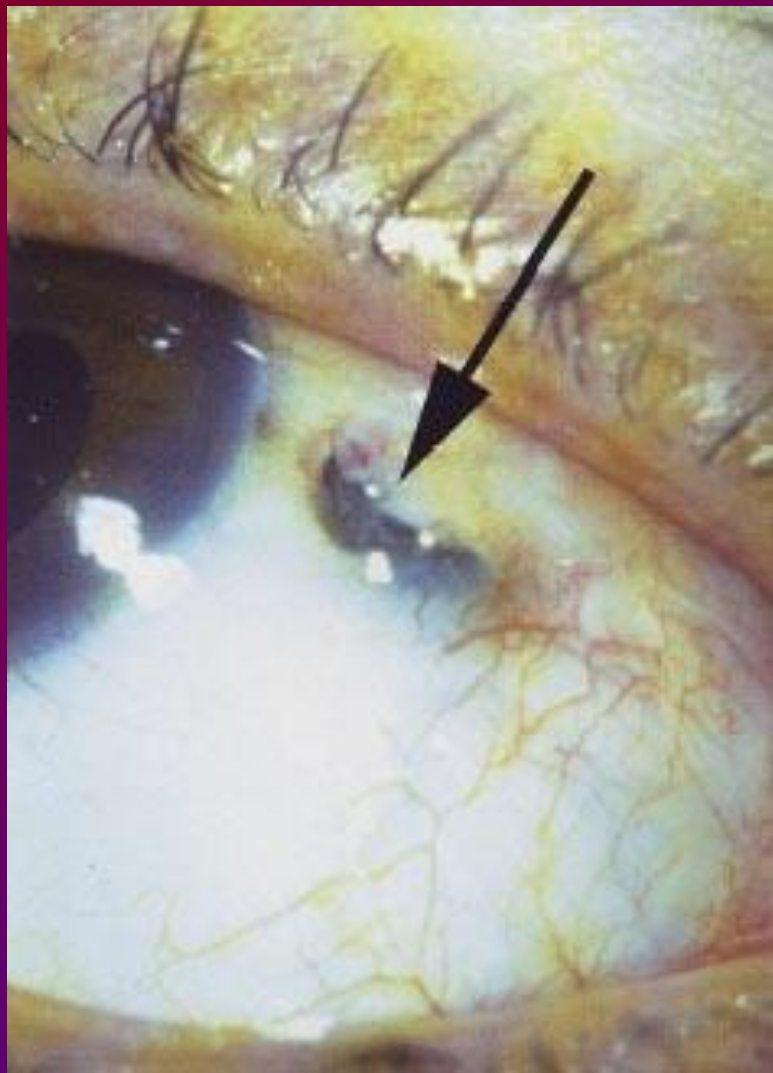
Intraocular foreign body

- *Suspect in all cases of penetrating injury*
- *Ask about accident circumstances-* work with hammer, cutting machines, other danger tools, explosion, car accident
- Usually metal particles
- RTG of the orbits
 - always in both projections: A-P and lateral
 - always when positive interview
- Ophthalmological emergency room
- USG, KT
- Surgical treatment

Intraocular foreign body



Intraocular foreign body

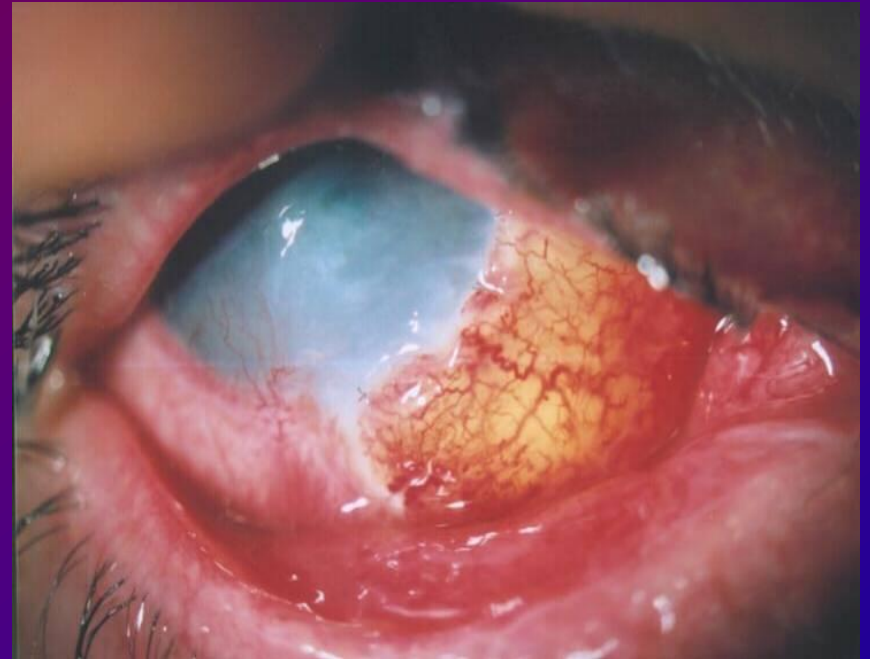
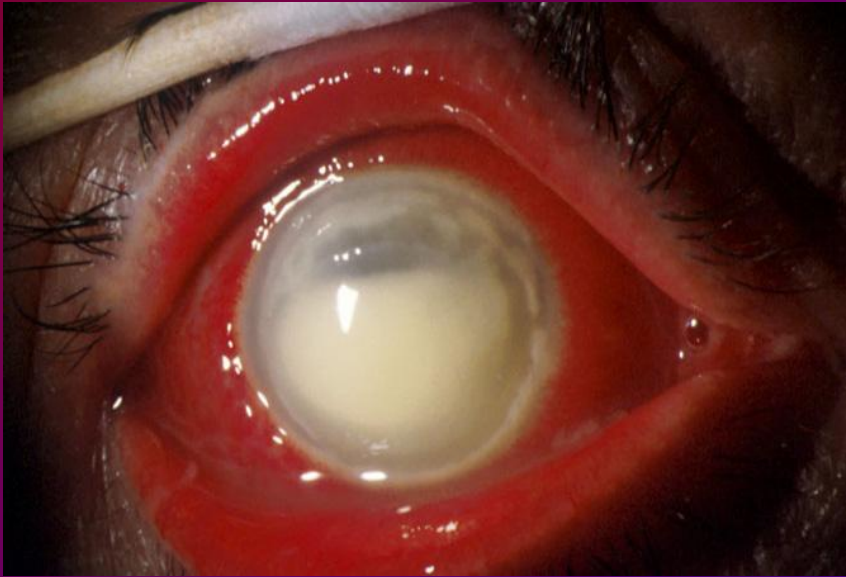

Chemical burns

alkali burns

- The most severe kind of burns
- mortar, ammonia, sodium hydroxide, lime, caustic soda
- Alkali quickly penetrate the cornea and bind with cell membrane lipids – damage of intraocular structures
- *Eye condition deteriorate in time*

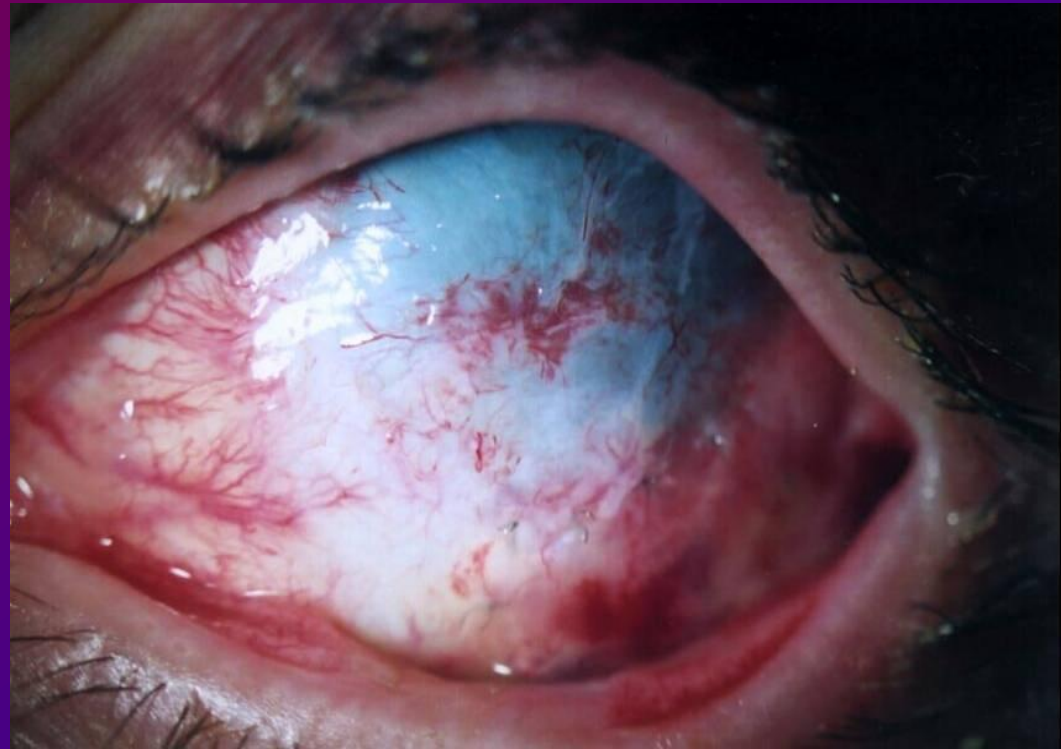
Chemical burn



Chemical burns

acid burns

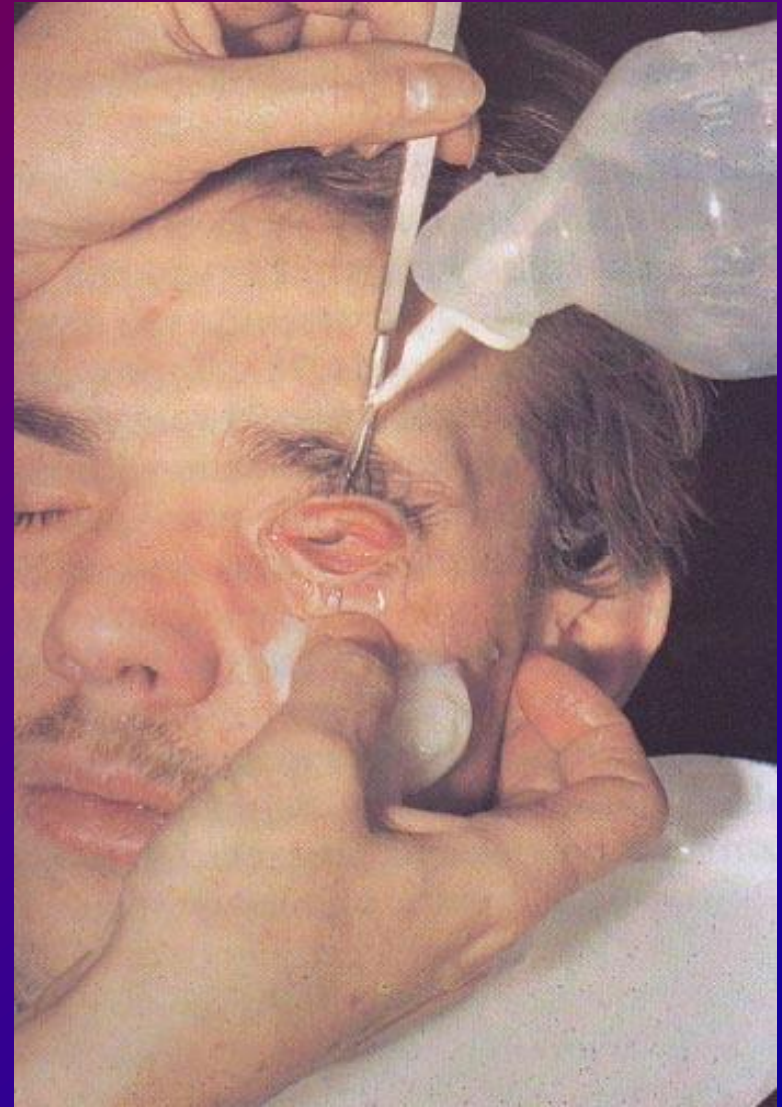
- usually hydrochloric acid, laboratory acids
- Less danger than alkali— cause denaturation of proteins which makes the barrier against penetrating of acid deeper into tissue



Chemical burns of the eye

Severity of eye damage depends from kind, amount and concentration of substance

and from quickness of first washing of eye surface



First aid in chemical burns of the eye

- **Abundant washing**(min. 2 liters) – *a.s.a.p.!* - at site of accident – water, milk, juice, etc.
- *Wide mechanical opening of lids is necessary for precise irrigating*
- Precise removing of all pieces of mortar
- It is necessary to **repeat washing** if the victim can not be transported to the ER in 30 min
- Quick transport to ophthalmological ER – *do not dress the eye.*

UV burn

- usually: while welding, quartz lamp (solarium), strong solar radiation on snow
- Symptoms after 6-10 h after exposition
- Severe pain, photophobia, blepharospasm, conjunctival hyperaemia, oedema of lids, corneal epithelial erosions

Treatment :

- Symptomatic only – analgetics, cold compress
- Symptoms usually pass in 24h

SUMMING UP...

Ocular trauma – in ca. 20% of all accidents

While helping victims of accidents:

- remember that the eyes may be injured too,
- protect eyes from additional damage

... SUMMING UP

- In case of blunt trauma of the eye always suspect and look for intraocular damage.
- Always suspect intraocular foreign body and look for it (RTG, USG) if there is such suggestion in interview or in post-traumatic signs.
- In case of **chemical burns** always remember about quick and abundant washing of the eye. It may influence further vision acuity.

THESE LOOK! BETTER ON YOU



Than
This



Thank you

REDUCE THE CHANCE OF EYE INJURY!